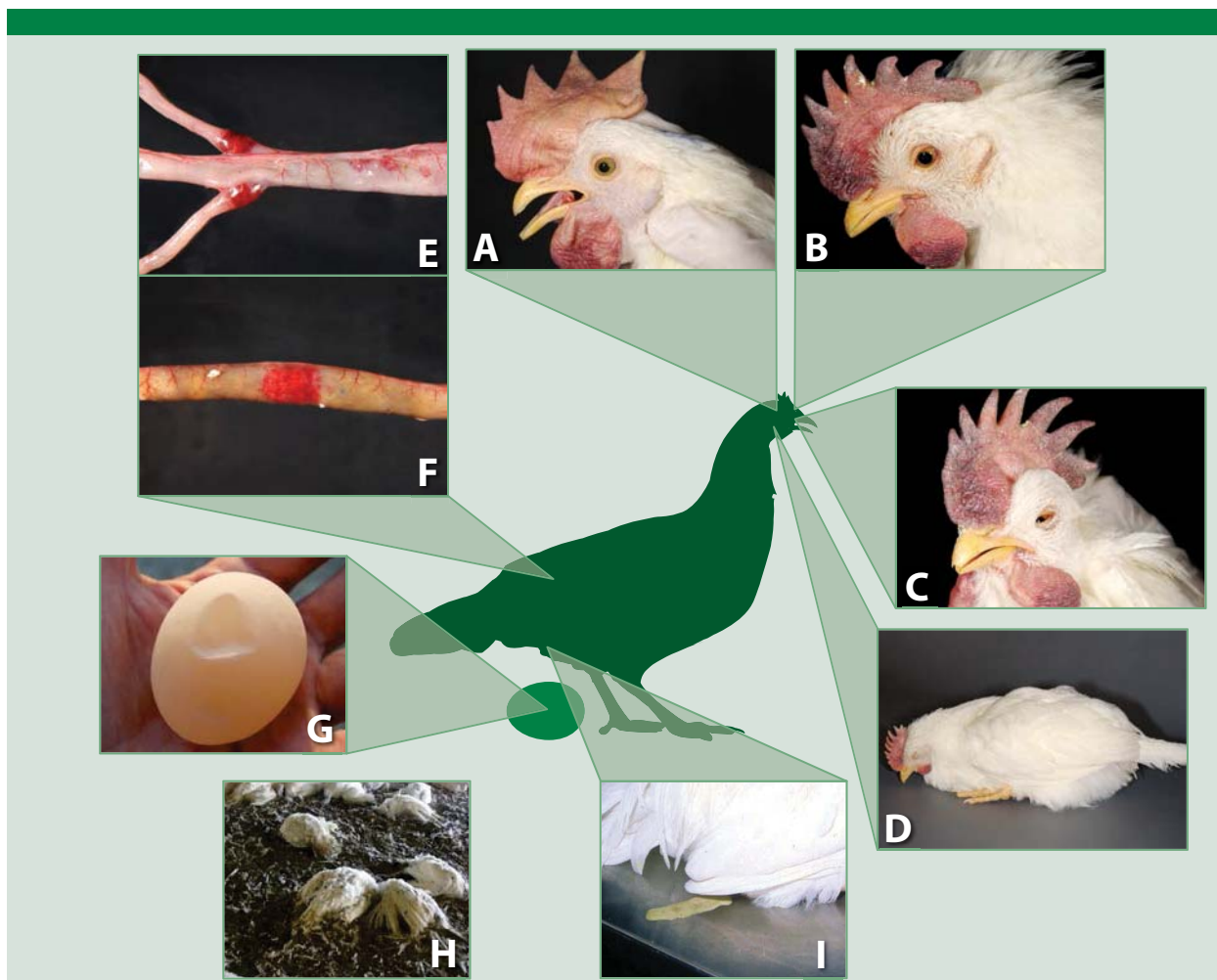


ND and HPAI Clinical Signs—Poultry



HPAI and ND Clinical Signs—Poultry

- A.** Sneezing, gasping for air, nasal discharge, and increased respiratory effort
- B.** Cyanosis of the wattle, comb, and legs. Swelling of the head, eyelids, comb, and wattle
- C.** Swelling of tissues around eyes and neck
- D.** Depression, muscular tremors, drooping wings, torticollis, circling, and complete paralysis
- E.** Hemorrhagic lesions of the gastrointestinal tract
- F.** Hemorrhagic lesions of the gastrointestinal tract
- G.** Decreased egg production, soft-shelled or misshapen eggs
- H.** Sudden death
- I.** Greenish, watery diarrhea

Fig. 6-12. Clinical signs of ND and HPAI among poultry. If you identify any of these signs and a suspicious history, call your State Animal Health Official and Assistant Director. (Use USDA's toll free number at 1-866-536-7593 for a local contact.) *Graphic illustration: Dani Ausen, Iowa State University; Photo sources: Plum Island Animal Disease Center (A, B, C, D, E, and F); USDA (G and H)*